

## Resolution of Sleep Bruxism using Biomimetic Oral Appliance Therapy: A Case Report

Felix Liao<sup>1</sup> and G Dave Singh<sup>2\*</sup>

<sup>1</sup>17115 Leesburg Pike, Suite 310, Falls Church, VA 22043, USA

<sup>2</sup>BioModeling Solutions, Inc., 17933 NW Evergreen Parkway, Suite 280, Beaverton, OR 97006, USA

\*Corresponding author: G Dave Singh, DDSc PhD DMD, BioModeling Solutions, Inc., 17933 NW Evergreen Parkway, Suite 280, Beaverton, OR 97006, USA, Tel: 971-302-2234; E-mail: [drsingh@drdavesingh.com](mailto:drsingh@drdavesingh.com)

Received date: May 08, 2015, Accepted date: Jun 13, 2015, Published date: Jun 21, 2015

Copyright: © 2015 Liao F, et al. This is an open-access article distributed under the terms of the Creative Commons Attribution License, which permits unrestricted use, distribution, and reproduction in any medium, provided the original author and source are credited.

### Abstract

**Background:** Evidence suggests that sleep bruxism is centrally regulated, and that the highest risk factor associated with sleep bruxism is obstructive sleep apnea. Current treatments for sleep bruxism include dental night-guards or occlusal splints, which are often provided without upper airway or sleep assessments. Methods: In this case report, we used biomimetic oral appliance therapy to address sleep bruxism by redeveloping the maxilla and repositioning the mandible in a 17 yr. old, female patient.

**Results:** The upper airway volume increased by 313% (from 7.7 cm<sup>3</sup> to 24.1 cm<sup>3</sup>) and the minimum upper airway cross-sectional area increased by 230% from (120 mm<sup>2</sup> to 276.5 mm<sup>2</sup>), which improved both sleep bruxism and orthodontic relapse.

**Conclusion:** We conclude that dentists and orthodontists can help in the recognition and treatment of both sleep bruxism and malocclusion, thereby preventing systemic co-morbidities associated with obstructive sleep apnea.

**Keywords:** Sleep bruxism; Nocturnal bruxism; Obstructive sleep apnea; Biomimetic; Oral appliance

### Abbreviations:

SB: Sleep Bruxism; OSA: Obstructive Sleep Apnea; AOB: Anterior Open Bite; CPAP: Continuous Positive Airway Pressure

### Introduction

Bruxism occurs in over 50% of children aged 3-5 yrs., with significant oral and systemic consequences [1]. In adults, a study that relied on self-reporting found that about 8% of a general sample admitted to sleep bruxism (SB) [2]. More specifically, it is thought that about 25% of patients diagnosed with obstructive sleep apnea (OSA) have SB [3]. Indeed, over 50% of patients with mild OSA and 40% of patients with moderate OSA have concomitant SB [4]. Therefore, it appears that SB is related to OSA.

It is thought that SB is a neural response to stress that is mediated via the jaws [5]. Indeed, resolution of episodes of apnea during sleep is thought to eliminate SB [6]. It has been shown in sleep studies that EEG signals spike 4s before an SB event [5], indicating that SB is a centrally-mediated event, and not simply a local, dental occurrence. In fact, the same study [5] showed tachycardia 10s after the SB event, suggesting that SB is associated with a stressor, possibly oxygen desaturation, during sleep. Interestingly, transient hypertension is also associated with SB, as the blood pressure increases by about 25% after SB events [7], indicating that SB is associated with sympathetic activation. It is also thought that SB is associated with micro-arousals during sleep [5], possibly related to upper airway obstruction.

In addition to the above, rhythmic masticatory muscle activity (RMMA) is thought to be secondary to a sequence of events in relation to micro-arousals [8] and, not surprisingly, nearly 90% of SB events occur during periods of sleep arousal. In an earlier study, RMMA was found to be 3 times higher in patients with SB than in controls. However, not all RMMA episodes are accompanied by tooth grinding, and many patients or family members may not be aware of this para-functional activity [8]. But it is thought that contractions of the masticatory muscles are associated with arousal and/or transient oxygen desaturation in patients with OSA [9]. Therefore, we surmise that SB is a sympathetic-activating event likely in response to hypoxia, and appears to be regulated centrally, not peripherally [10].

This case report describes the clinical management of a young patient with SB and anterior open bite (AOB) 3 yrs. after conventional orthodontic treatment, showing resolution of the former and concomitant improvement of the latter.

### Case Report

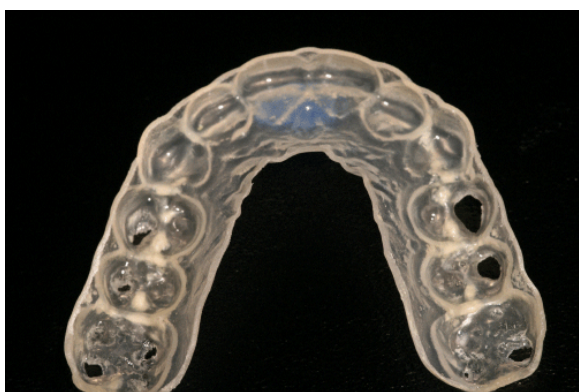Aside from continuous positive airway pressure (CPAP), oral appliance therapy helps to maintain the upper airway during sleep. But, some cases can develop unwanted occlusal changes and possibly temporomandibular joint dysfunction following long-term oral appliance use [11].

This case report refers to a 17 yr. old female (Figure 1) who gave informed consent and signed a patient release form. She was initially referred by a Chiropractor to our dental office with a chief complaint of bruxism.



**Figure 1:** Note the counterclockwise rotation of the head. Sclera is visible below the iris on both sides, suggesting midfacial hypoplasia. The lips apart posture indicates mouth-breathing.

The patient admitted to grinding her teeth and had worn holes through her night-guard (Figure 2). Screening revealed a history of orthodontic treatment at age 14 yrs. Currently, the patient exhibited a significant degree of orthodontic relapse, presenting as AOB. She also admitted to snoring while asleep, as well as having neck and shoulder pain. The patient had a social history of being a tennis player.

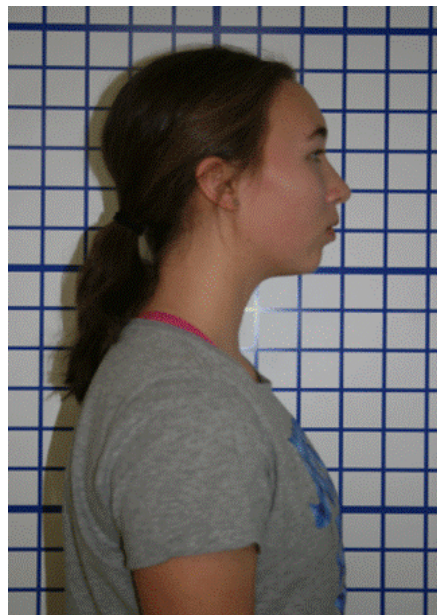

**Figure 2:** The patient had worn holes through her night-guard, revealing a history sleep bruxism.

### Examination and Assessment

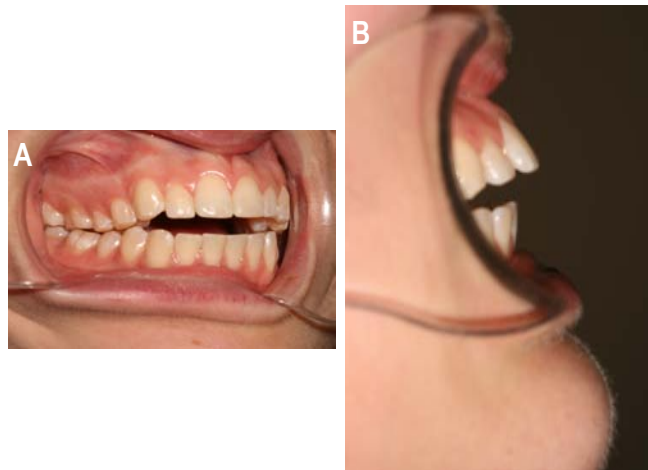
After the patient completed a psychometric assessment in the form of an Epworth Sleepiness Scale (ESS) questionnaire, physical and 3D cone-beam CT scan (i-CAT Imaging Sciences International, PA)

evaluations were undertaken, including 3D analysis (Invivo5 software, Anatomage Inc., San Jose, CA), which revealed the following findings; An ESS total score of 10. Forward head posture (Figure 3) with counterclockwise rotation of the head (Figure 1), indicating cervical subluxation.



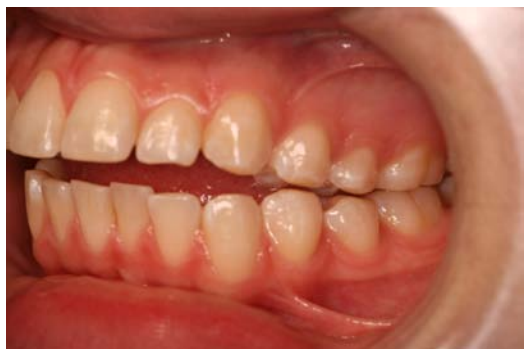**Figure 3:** Counterclockwise rotation of the head from lateral aspect, revealing forward head posture and mandibular retrognathia.

Anterior open bite with anterior crowding (Figure 4A and 4B), indicating orthodontic relapse.



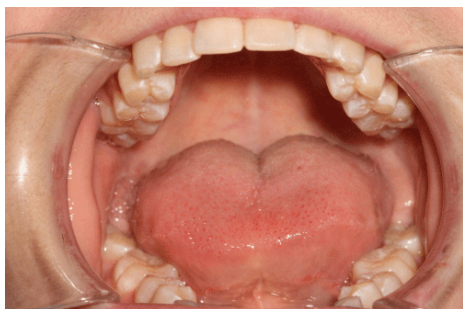**Figure 4:** (A) The anterior open bite is evident with minor anterior crowding in the upper arch, indicating orthodontic relapse. (B) The anterior open bite is evident from the lateral aspect, indicating orthodontic relapse.

Flattened cusps of posterior teeth (Figure 5), indicating sleep bruxism.



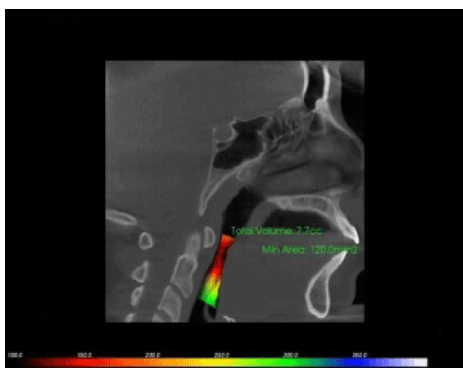
**Figure 5:** Note the flattened cusps of posterior teeth, indicating sleep bruxism.

Uvula not visible with mouth open (Figure 6) with Mallampati class IV, suggesting upper airway obstruction.



**Figure 6:** The uvula is not visible with mouth open (Mallampati class IV), suggesting upper airway obstruction.

Nasal and upper airway obstruction with an upper airway volume of 7.7 cm<sup>3</sup> and a minimum cross-sectional area of 120 mm<sup>2</sup> (Figure 7).



**Figure 7:** An upper airway volume of 7.7 cm<sup>3</sup> and a minimum cross-sectional area of 120 mm<sup>2</sup> indicates a degree of upper airway obstruction.

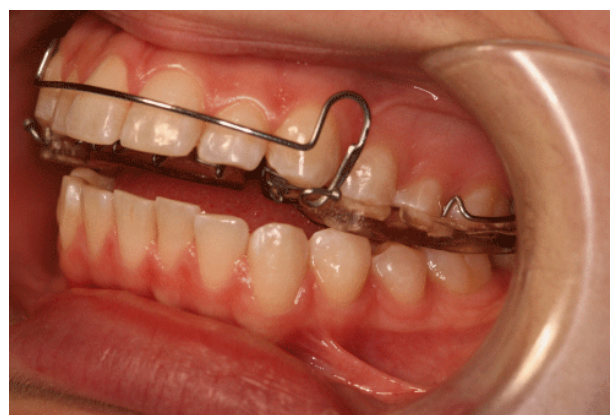## Diagnosis

The working and differential diagnoses in this case included; Class I malocclusion with anterior open bite (apertognathia), Maxillary hypoplasia and mandibular retrognathia, Obstructive sleep apnea with hypersomnia, Mandibular dyskinesia, and Cervicalgia.

Therefore, a comprehensive treatment plan was formulated as noted below.

## Treatment

The patient was advised to improve her sleep hygiene, including black-out blinds in the bedroom and going to sleep by 11 pm. She was also instructed on keeping her lips closed as much as possible, particularly while at rest. In addition, nutritional counseling [12,13] was implemented. Next, a biomimetic, upper appliance was prescribed (DNA appliance®, Figure 8).

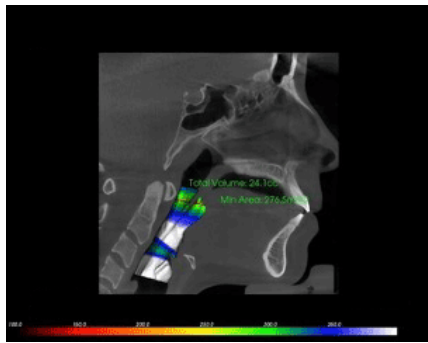


**Figure 8:** The biomimetic, upper appliance that was prescribed is shown in situ.

The DNA appliance system is designed to correct maxillo-mandibular underdevelopment in both children and adults [14-19]. The patient was instructed to wear the DNA appliance during the late afternoon, early evening and at nighttime during sleep (for approx. 10-12 hrs. in total), but not during the day time and not while eating, partly in line with the circadian rhythm of tooth eruption [20], although this only occurs in children. In addition, a facemask was utilized to protract the maxilla [21]. The patient reported for review and the biomimetic appliance was adjusted every 4 weeks, approximately. At each monthly follow-up, examination for the progress of midfacial development was recorded. Adjustments to the device were performed to optimize its efficacy. Only gentle pressures were transmitted to the teeth, and the functionality of the device was checked with the subject activating a mild force on biting. The patient was encouraged to maintain the sleep, postural and nutritional protocols outlined at the start of treatment.

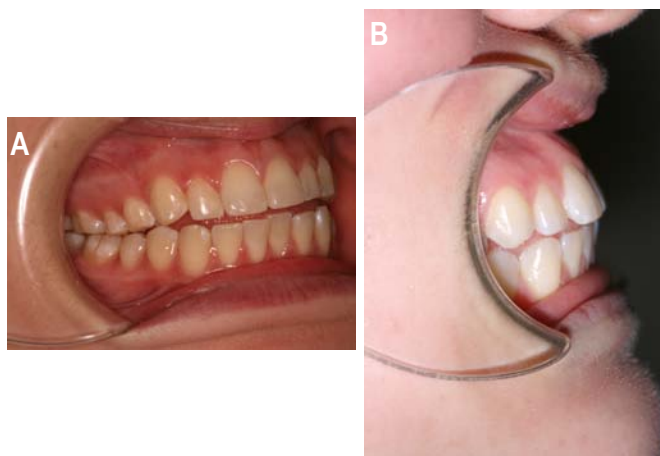
## Results

After 15 months of active treatment, the ESS total score decreased from 10 to 4, the upper airway volume increased from 7.7 cm<sup>3</sup> to 24.1 cm<sup>3</sup> and the minimum cross-sectional area increased from 120 mm<sup>2</sup> to 276.5 mm<sup>2</sup> (Figures 7 and 9).



**Figure 9:** After 15 months of active treatment, the upper airway volume increased to 24.1 cm<sup>3</sup> (from 7.7 cm<sup>3</sup>) and the minimum cross-sectional area increased to 276.5 mm<sup>2</sup> from 120 mm<sup>2</sup> (as shown in Figure 7 above).

Thus, the upper airway volume increased by 313% and the minimum upper airway cross-sectional area increased by 230%. Moreover, the patient reported that she was no longer grinding her teeth and was no longer snoring at night. In addition, she noticed an improved facial appearance and smile esthetics (Figure 10A and 10B).



**Figure 10:** (A) Significant improvement of the anterior open bite, which lays the foundation for final occlusal interdigitation and anterior coupling, using conventional orthodontic techniques. (B) Significant improvement of the anterior open bite from the lateral aspect is evident.

Furthermore, the patient reported that she woke up feeling refreshed and her athletic performance during tennis matches appeared to have improved also.

## Discussion

Currently, it is thought that preventive therapy cannot effectively cure sleep bruxism but various treatment protocols for its management are available [22]. This particular case report represents a patient who followed all treatment recommendations conscientiously,

and her progress and results appear to reflect her pursuit of health. However, a major limitation of this case report is the lack of a PSG study to document bruxism and OSA at both the baseline and post-treatment phases. However, psychometric measures, such as an Epworth Sleepiness Scale questionnaire were used to confirm the presence of bruxism, its severity and daytime sleepiness. In addition, the patient admitted to grinding her teeth, had worn holes through her night-guard (Figure 2), and the flattened cusps of her posterior teeth (Figure 5) were indicative of sleep bruxism. As a result of biomimetic oral appliance therapy, her upper airway was developed (Figures 7 and 9) so that mouth breathing was corrected and she could revert back to nasal breathing. This change in function appears to have resolved her chief concern of sleep bruxism. In fact, a comparable finding was reported in children that underwent a similar procedure for bruxism [23]. But, in addition, the nasal mode of breathing allowed her lips to contact gently while at rest. This oral posture permitted the tongue to sit in the palate, which is a prerequisite for the resolution of AOB, as noted in this particular case (Figure 10A and 10B).

Currently, the patient is being monitored for long term follow up, and is continuing with atlas-orthogonal chiropractic care as needed. Specifically, an overnight sleep study will be undertaken to assess the patient's sleep architecture and identify any signs of OSA. Indeed, a multi-disciplinary approach will be adopted. For example, it has been shown that both craniofacial [24] and systemic [25] improvements can be achieved using a combination of chiropractic adjustment and biomimetic oral appliance therapy. In addition, oral myofunctional therapy can correct tongue posture and behavior [26,27]. Furthermore, development of the lower arch may be required, using a lower appliance to permit arch re-coordination prior to final occlusal detailing with a finishing phase of orthodontics.

## Conclusion

Micro-arousals during sleep are considered to be one of the main factors initiating nocturnal jaw-closing muscles activation or bruxism, which may be related to neurotransmitter and basal ganglia disorders [28]. Therefore, further studies are needed to clarify the pathophysiology of SB and develop new protocols to target therapy for patients with concomitant SB and OSA. A multi-disciplinary approach may be appropriate for patients that present to a dental office with issues relating to SB. The protocol described in this article may also be applicable to cases of posterior open bite associated with mandibular advancement appliance therapy for the management of OSA. That premise remains as the basis for future studies.

## Acknowledgement

This work was support by a grant to Dr Felix Liao by The PACE Institute, Oregon, USA, a non-profit entity.

## References

1. Hachmann A, Martins EA, Araujo FB, Nunes R (1999) Efficacy of the nocturnal bite plate in the control of bruxism for 3 to 5 year old children. J Clin Pediatr Dent 24: 9-15.
2. Ohayon MM, Li KK, Guilleminault C (2001) Risk factors for sleep bruxism in the general population. Chest 119: 53-61.
3. Subramanian S, Rao S, Majid H, Casturi L, Guntupalli B, et al. (2009) Prevalence and gender and ethnic variance of bruxism and gastroesophageal reflux disease (GERD) in obstructive sleep apnea. Chest 136 (4MeetingAbstracts); 69S.

4. Sjöholm TT, Lowe AA, Miyamoto K, Fleetham JA, Ryan CF (2000) Sleep bruxism in patients with sleep-disordered breathing. *Arch Oral Biol* 45: 889-896.
5. Bader GG, Kampe T, Tagdae T, Karlsson S, Blomqvist M (1997) Descriptive physiological data on a sleep bruxism population. *Sleep* 20: 982-990.
6. Oksenberg A, Arons E (2002) Sleep bruxism related to obstructive sleep apnea: the effect of continuous positive airway pressure. *Sleep Med* 3: 513-515.
7. Nashed A, Lanfranchi P, Rompré P, Carra MC, Mayer P, et al. (2012) Sleep bruxism is associated with a rise in arterial blood pressure. *Sleep* 35: 529-536.
8. Lavigne GJ, Huynh N, Kato T, Okura K, Adachi K, et al. (2007) Genesis of sleep bruxism: motor and autonomic-cardiac interactions. *Arch Oral Biol* 52: 381-384.
9. Kato T, Katase T, Yamashita S, Sugita H, Muraki H, et al. (2013) Responsiveness of jaw motor activation to arousals during sleep in patients with obstructive sleep apnea syndrome. *J Clin Sleep Med* 9: 759-765.
10. Lobbezoo F, Naeije M (2001) Bruxism is mainly regulated centrally, not peripherally. *J Oral Rehabil* 28: 1085-1091.
11. Pliska BT, Nam H, Chen H, Lowe AA, Almeida FR (2014) Obstructive sleep apnea and mandibular advancement splints: occlusal effects and progression of changes associated with a decade of treatment. *J Clin Sleep Med* 10: 1285-1291.
12. Price WA (2008) Nutrition and physical degeneration. Price-Pottenger Nutrition Foundation
13. Fallon S (2003) Nourishing Traditions Diet. New Trends Publishing, (2nd edn).
14. Singh GD, Lipka G (2009) Case Report: Introducing the wireframe DNA appliance™. *J Am Acad Gnathol Orthop* 26: 8-11.
15. Singh GD, Wendling S, Chandrashekhar R (2011) Midfacial development in adult obstructive sleep apnea. *Dent Today* 30: 124-127.
16. Singh GD, Utama J (2013) Effect of the DNA Appliance™ on migraine headache: case report. *Int J Orthod Milwaukee* 24: 45-49.
17. Singh GD, Cress SE (2013) Craniofacial enhancement using a biomimetic oral appliance. *Dent Today* 32: 92-94.
18. Singh GD, Callister JD (2013) Effect of a maxillary appliance in an adult with obstructive sleep apnea: a case report. *Cranio* 31: 171-175.
19. Harris WG, Singh GD (2013) Resolution of 'gummy smile' and anterior open bite using the DNA appliance™: Case Report. *J Amer Orthod Soc* 30-34.
20. Proffit WR, Frazier-Bowers SA (2009) Mechanism and control of tooth eruption: overview and clinical implications. *Orthod Craniofac Res* 12: 59-66.
21. Baccetti T, McGill JS, Franchi L, McNamara JA Jr, Tollaro I (1998) Skeletal effects of early treatment of Class III malocclusion with maxillary expansion and face-mask therapy. *Am J Orthod Dentofacial Orthop* 113: 333-343.
22. Afrashtehfar K, Afrashtehfar CD, Huynh N (2014) Managing a patient with sleep bruxism. *J Can Dent Assoc* 80: e48.
23. Bellerive A, Montpetit A, El-Khatib H, Carra MC, Remise C, et al. (2015) The effect of rapid palatal expansion on sleep bruxism in children. *Sleep Breath*.
24. Singh GD and Chapman DC. Craniofacial changes after combined atlas-orthogonal and biomimetic oral appliance therapy. *Annals Vert Sub Res.* 4, 112-118, 2014.
25. Chapman DC and Singh GD. Combined effect of a biomimetic oral appliance and atlas orthogonist cervical adjustment on leg lengths in adults. *Annals Vert Sub Res.* 46-50, 2013.
26. Moeller JL, Coceani-Paskay L, Gelb ML (2014) Myofunctional Therapy: A Novel Treatment of Pediatric Sleep-Disordered Breathing. *Sleep Med Clin* 9: 235-243.
27. Guillemainault C, Huang YS, Monteyrol PJ, Sato R, Quo S, et al. (2013) Critical role of myofascial reeducation in pediatric sleep-disordered breathing. *Sleep Med* 14: 518-525.
28. Kostrzewa-Janicka J, Jurkowski P, Zycinska K, Przybyłowska D, Mierzwińska-Nastalska E. Sleep-Related Breathing Disorders and Bruxism. *Adv Exp Med Biol.* 2015 May 29. [Epub ahead of print]